

Research Journal of Pharmaceutical, Biological and Chemical Sciences

Scleroderma Overlap Syndrome: A Rare Case Report.

Sakthi Selva Kumar S^{*}, Bhargavi MV, Palaniandavan S, Selva Gamber.

Department of General Medicine, Sree Balaji Medical College and Hospital, Bharath University, Chennai, Tamil Nadu, India.

ABSTRACT

An overlap syndrome¹ is an entity that satisfies the criteria of at least two connective tissue diseases. Scleroderma is a rare condition, occurring most commonly in females, the onset of which is usually heralded by Raynaud's phenomenon, cutaneous sclerosis or arthritic symptoms. Sjogren's syndrome is a chronic autoimmune disease in which the body's white blood cells destroy the exocrine glands, specifically the salivary and lacrimal glands, that produce saliva and tears, respectively. We report a case of scleroderma in association with Sjogren's syndrome in view of its rarity.

Key words: Sjogren's syndrome, Systemic sclerosis, autoimmune disease, Overlap syndrome.

**Corresponding author*

CASE REPORT**History**

A Middle aged women came to the out-patient department with complaints of difficulty in swallowing food and burning sensation of the mouth for one year. It was progressively increasing, due to which she had loss of weight, around 12 kg in 1 year duration. She had difficulty in opening her mouth fully. She also gave history of diminished vision, photophobia, redness and gritty sensation of eyes for about a year. She also had Raynaud's phenomena, arthralgia, joint stiffening, itching and dry skin and multiple ulcers in finger tips and toes. She had a fall while climbing stairs 6 months ago and sustained fracture of right wrist for which she took native treatment. She had persistent swelling and severe pain in right wrist. No significant past medical, surgical or family history.

Examination

On examination she was found to be thin built and pale. She was hemodynamically stable. Skin was thin, dry with diffuse hyper pigmentation. Auto amputated right second toe and right ring finger present. Multiple ulcers in left hand and left foot. Mouth opening was restricted with poor oral hygiene and dry eyes. Old fracture with malunion in right wrist with swelling and tenderness. Figure-1-8

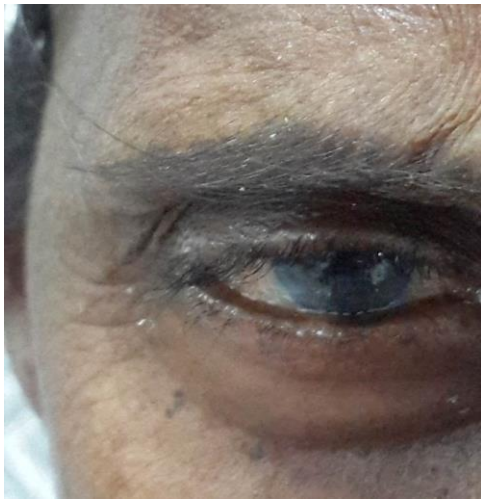

Fig.1

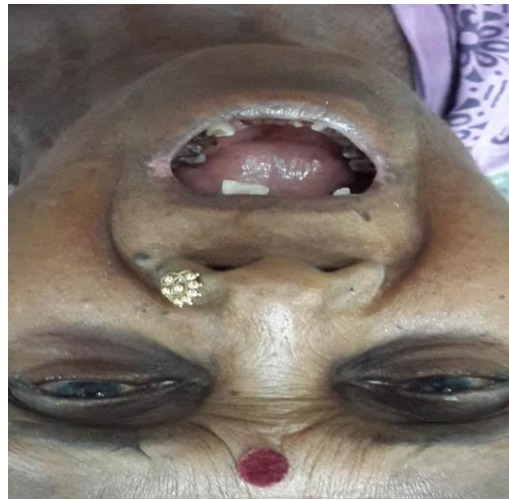

Fig.2

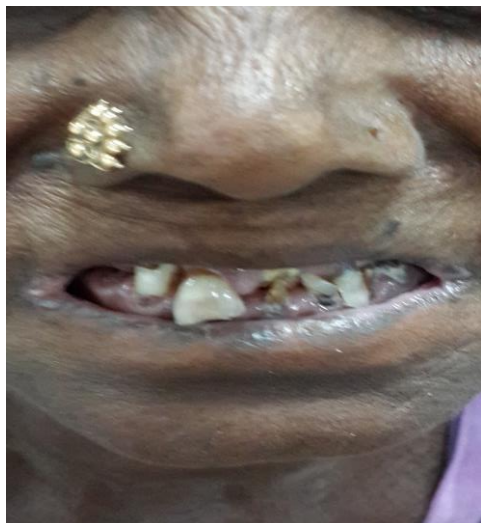

Fig.3

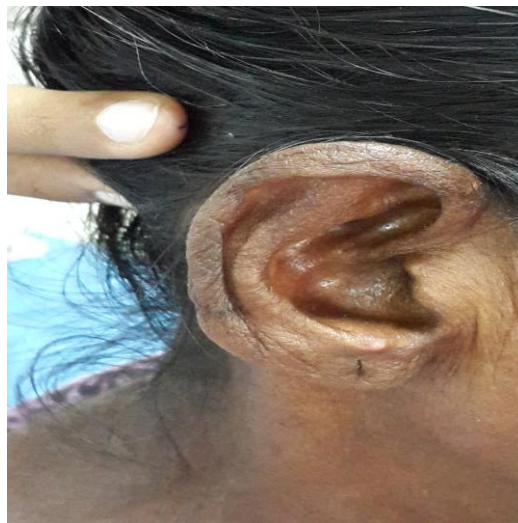

Fig.4

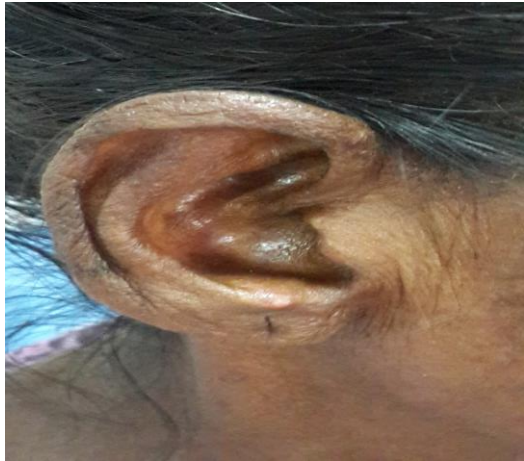

Fig.5



Fig.6

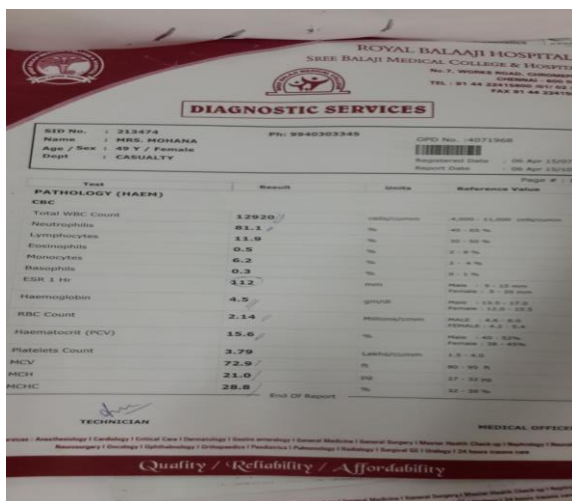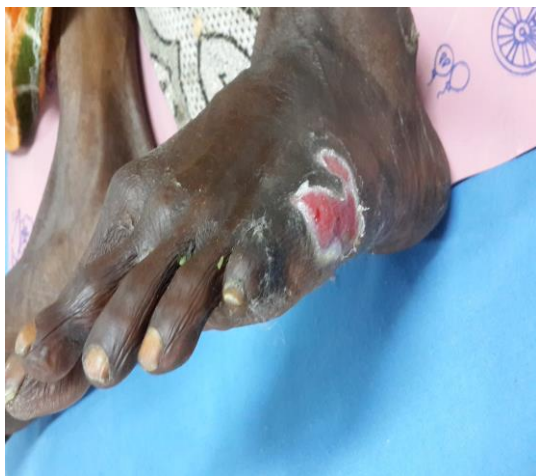


Fig.7

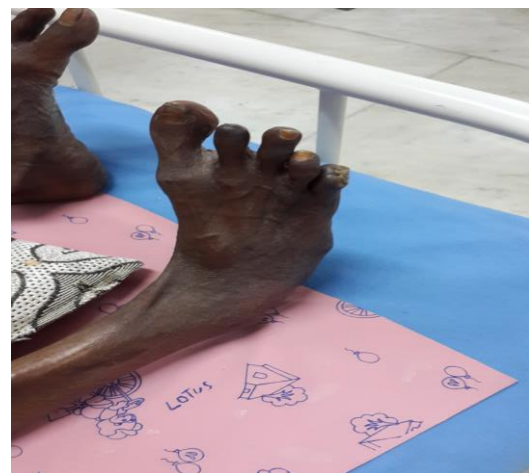


Fig.8

Course:- On investigating, Hemoglobin- 4.5 g/dl, PCV 15.6, % TC- 12920 cells/cu.mm neutrophil -81%. ESR- 112 mm. Urea 37mg/dl. Creatinine 1.3mg/dl. Urine protein present. Peripheral smear showed normocytic normochromic and microcytic fragmented RBC's with neutrophilic leucocytosis. Schirmer's 1 test positive. Slit lamp examination revealed multiple corneal ulcerations. Wound swab culture was done which showed had proteus species. . Figure 9-13



| Test | Result | Units | Reference Value |
|-------------------------|--------|-------------------------|-----------------|
| PATHOLOGY (HAEM) | | | |
| CBC | | | |
| Total WBC Count | 12920 | cells/mm ³ | 4,000 - 11,000 |
| Neutrophils | 81.1 | % | 50 - 70 |
| Lymphocytes | 11.0 | % | 20 - 40 |
| Eosinophils | 0.5 | % | 1 - 5 |
| Monocytes | 6.2 | % | 2 - 8 |
| Platelets | 0.3 | % | 1 - 3 |
| ESR 1 Hr | 112 | mm | 0 - 10 |
| Hemoglobin | 4.5 | g/dl | 12.0 - 16.0 |
| RBC Count | 2.14 | million/mm ³ | 4.0 - 5.5 |
| Hematocrit (PCV) | 15.0 | % | 37 - 47 |
| Platelets Count | 3.79 | Lakhs/mm ³ | 1.5 - 4.0 |
| MCV | 72.9 | fL | 80 - 100 |
| MCH | 21.0 | pg | 27 - 32 |
| MCHC | 28.8 | g/dl | 32 - 36 |

Fig.9



| Test | Result | Units | Reference Value |
|------------------------------|--------|-------|-----------------|
| BIOCHEMISTRY | | | |
| BLOOD SUGAR (R) | 92 | mg/dl | 80 - 120 |
| UREA | 37 | mg/dl | 15.0 - 45.0 |
| CREATININE | 1.3 | mg/dl | 0.7 - 1.3 |
| REUR ELECTROLYTES | | | |
| Sodium (Na ⁺) | 130.3 | mEq/l | 135 - 140 |
| Potassium (K ⁺) | 3.65 | mEq/l | 3.5 - 5.3 |
| Chlorides (Cl ⁻) | 110.4 | mEq/l | 96 - 107 |

Fig.10

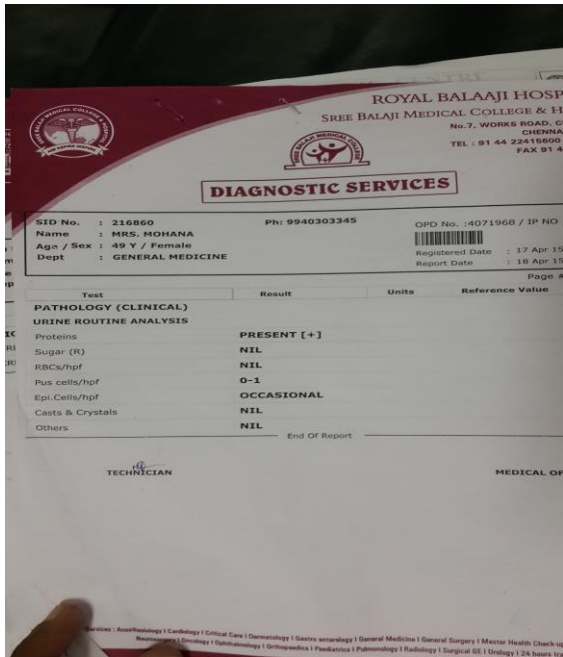


Fig.11

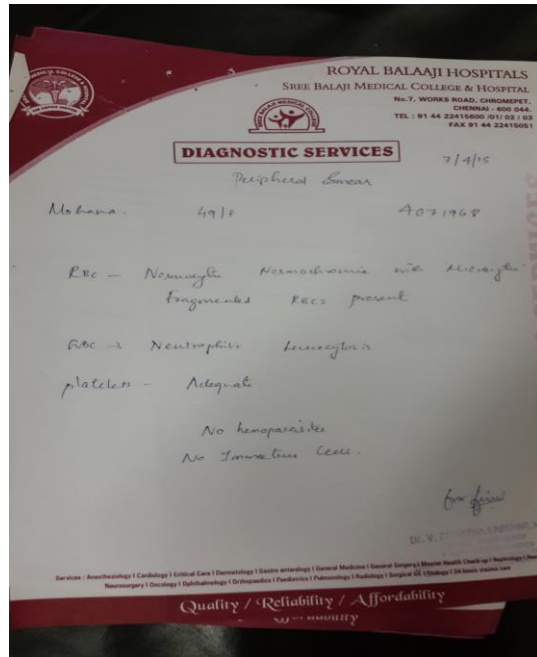


Fig.12

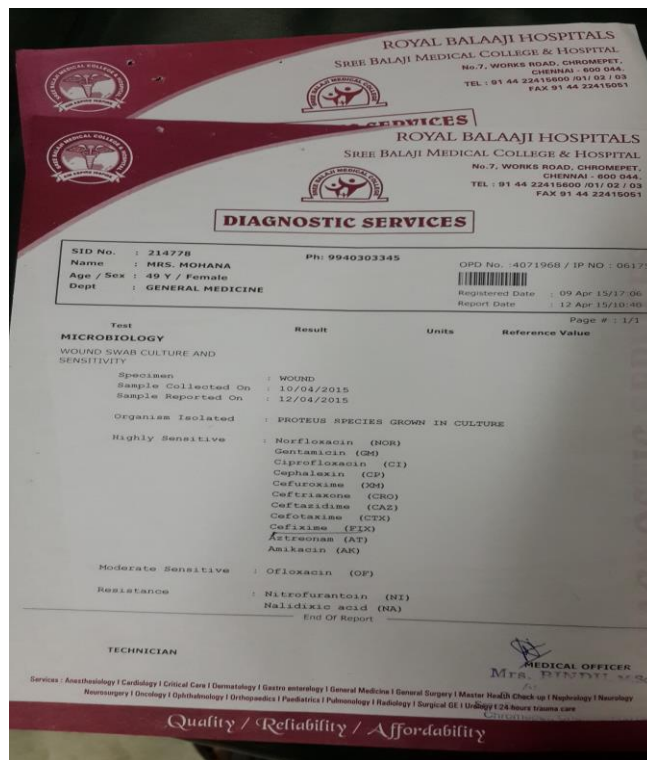


Fig.13

Serological tests -- ANA positive 1 in 100 dilution (2+) with granular nucleoplasm pattern .Anti-centromere positive, anti-topoisomerase negative. Anti SSA, anti ssb positive. Anti dsdna – negative. Patient was managed symptomatically and was started on steroids and serial blood transfusions were given. Artificial tear substitutes were given. . Figure 14-18




Fig.14




Fig.15




Fig.16



Fig.17



Fig.18

Orthopedic opinion was obtained for her and was found to have post traumatic sudeck's osteodystrophy with Charcot's degenerative arthritis and osteoporosis and advised zolidronic acid infusion which was done. Figure 19,20

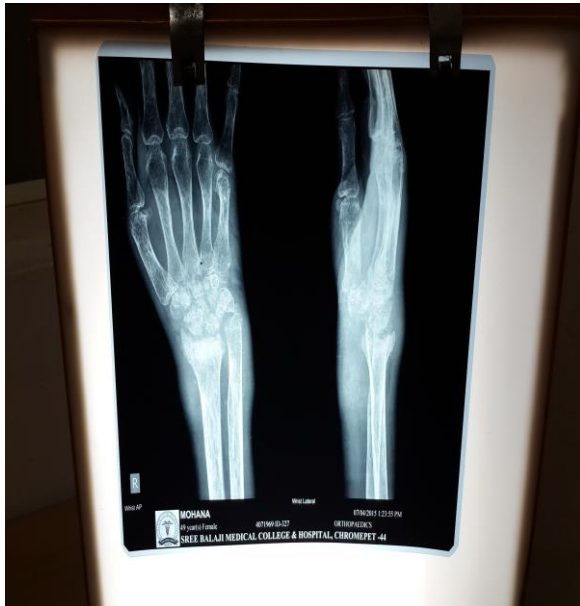

Fig.19

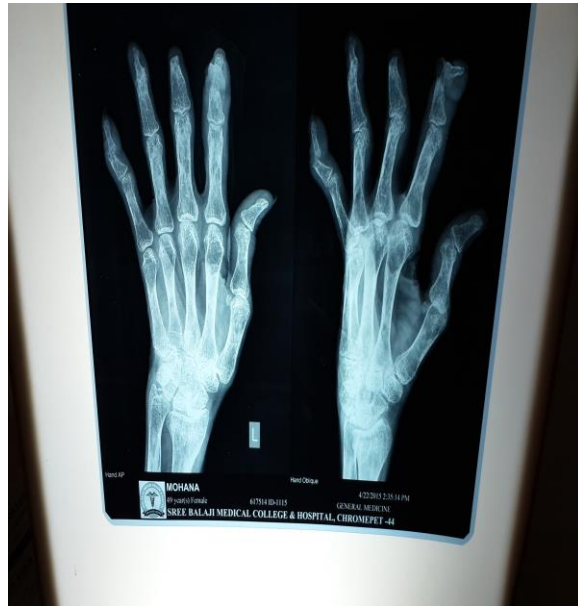

Fig.120

Anesthetist opinion obtained and stellate ganglion block of right wrist was done for the chronic pain. Now patient is symptomatically better and is on regular follow up.

Case Discussion

Systemic sclerosis

Systemic sclerosis (SSc) is a multisystem autoimmune disease in which there is increased fibroblast activity resulting in abnormal growth of connective tissue. This causes vascular damage and fibrosis occurring in skin, the gastrointestinal (GI) tract and other internal organs. SSc is classified into two main types, according to the extent of skin involvement [2]. A) Limited cutaneous systemic sclerosis (lcSSc) B) Diffuse cutaneous systemic sclerosis (dcSSc), C) Other types - like *systemic sclerosis sine scleroderma*, in which there is internal organ involvement without the skin changes. [3]

Clinical features [3,4]

Fatigue, weight loss, skin features like swelling of fingers and toes, sclerodactyly, reduced hand movements. Fingertips may have pits, ulcers or loss of bulk from finger pads. Raynaud's phenomenon. Calcinosis, tightening of facial skin. Tight lips (microstomia), Telangiectasia. 'Salt and pepper' appearance of skin.: Musculoskeletal features - Joint pain and swelling. Myalgia and joint restriction, contractures and muscle atrophy, tendon friction rubs. GI features: Heartburn and reflux esophagitis, esophageal scarring and dysphagia. Pulmonary features: ILD-Occurs in as many as 75% of scleroderma patients [3]..PAH-Occurs in about 10-15% of patients with scleroderma [3]. A leading cause of death in SSc.

Investigations

Blood tests [4]

FBC, ESR and CRP with baseline biochemistry and renal function. Auto antibodies: Antinuclear antibody positive in 90-95% but not specific to SSc. Other auto antibodies in SSc [3]:- Anti-topoisomerase 1 antibody, Anti-centromere antibody (ACA), Anti-RNA polymerase III antibody (There is a strong association

between presence of anti-RNA polymerase III antibodies and the development of scleroderma renal crisis which helps to identify at-risk patients. [5]), Anti-fibrillarin (anti-U3RNP) antibody - associated with heart involvement, pulmonary hypertension, kidney involvement and myositis. Anti-PM-Scl antibody - strongly associated with the combination of myositis and scleroderma. Anti-U1RNP (anti-nRNP) antibody - associated with joint involvement and overlap syndromes.

Sjogren's syndrome

Sjogren's syndrome (SS) is a systemic autoimmune disorder characterized by lymphocyte proliferation and infiltration of exocrine glands [6]. This immune-mediated attack leads to the development of xerostomia (dry mouth) and keratoconjunctivitis sicca (dry eyes), which is the hallmark. Etiopathogenesis is to be due to influence of combination of genetic, environmental and hormonal factors [7]. It occurs in females more than males. Sjogren's syndrome may cause skin, nose, and vaginal dryness, and may affect other organs of the body, including the kidneys, blood vessels, lungs, liver, pancreas, peripheral nervous system (distal axonal sensorimotor neuropathy) and brain.

Sjogren's syndrome, is characterized by decreased levels of IL-1ra in saliva, which could be responsible for mouth inflammation and dryness.[8] Patients with secondary Sjogren's syndrome often exhibits signs and symptoms of their primary rheumatic disorders, such as systemic lupus erythematosus, rheumatoid arthritis, or systemic sclerosis [9].Diagnosed by Ocular symptoms and signs ,Oral Symptoms and signs with Histopathology of Lip biopsy showing focal lymphocytic sialoadenitis and having auto antibodies (at least one) - Anti-SSA (Ro) or Anti-SSB (La)

Diagnosis of Sjogren's syndrome (SS) is difficult as there is no uniformly accepted definition for this syndrome. Our patient satisfied many of the revised international criteria's for diagnosis of SS. She had evidence of a systemic autoimmune disorder in the form of 1:100 ANA which is significant in old individuals. Positive Schirmer's test indicating ocular dryness is a pointer towards Sjogren's syndrome.^[10] Alexander and Provost (1983) reviewed the dermatological findings and found 9% of cases presenting as erythema multiforme, other skin changes being purpura (45%), urticaria (32%), digital infarcts (9%), erythema perstans (4%), erythema nodosum (4%), erythematosus macules (4%), and subcutaneous nodules (4%). Lung involvement is known to occur in SS and the respiratory involvement is usually in the form of chronic bronchitis, lymphocytic interstitial pneumonitis, and pleural effusions [7, 8] SS overlap patients had a 3 fold higher risk of musculoskeletal manifestations than patients with limited cutaneous subtype and twice the risk of patients with diffuse cutaneous subtype. Sicca syndrome is common in SSc (68%), but only 14% of SSc patients fulfill the criteria of Sjogren's syndrome [11]. The main feature in primary SS is lymphocytic infiltration of the salivary glands. In contrast, half of SSc patients had salivary gland fibrosis that correlated with more severe SSc and higher mortality rate. Lower titers of anti-SS-A and/or anti-SS-B antibodies did not modify the severity of arthritis, neuropathy or cryoglobulinemia in SSc/SS overlap. Patients with SSc/SS mainly had LcSSc with a low frequency of lung fibrosis. In SS patients the development of scleroderma was preceded by the appearance of Anti centromere antibody for several years. In patients with SSc/SS, coexistence with primary biliary cirrhosis has been described. There are no data regarding biological therapy in SSc/SS overlap. Experience with anti-TNF α drugs in SS revealed conflicting results. Rituximab was effective in open-label trials in the treatment of primary SS, interestingly mostly in the control of systemic (including ILD) features. There have been many studies indicating the association between these two entities. [12-15]

CONCLUSION

Only a few and controversial data are available about Sjogren's characteristics in patients with SSc. These controversial data on characteristics of SS associated with SSc are probably due to the lack of a consensual definition of sSS until recently. SS is now clearly defined by criteria from the American-European consensus group (AECG)[16] published in 2002 and thus, the characteristics of patients with SS and SSc can now be studied. This association does not modify the severity of SS. However, SSc seems to be less serious when it is associated with SS. Moreover, the two diseases are often accompanied by other autoimmune diseases or the presence of other auto-antibodies, which suggests a spreading of autoimmunity that could be associated with a peculiar genetic profile. The definition of scleroderma overlap syndrome is important, especially in patients which need high dose corticosteroids for complications of a CTD.



REFERENCES

- [1] Maddison PJ. Current Opinion in Rheumatology 1991;3 (6):995–1000.
- [2] LeRoy EC, Black C, Fleischmajer R, et al. J Rheumatol 1988;15: 202-205.
- [3] Understanding and managing scleroderma; Scleroderma Society, Revised October 2008
- [4] Hinchcliff M, Varga J. Am FAM Physician 2008;78(8):961-8.
- [5] Shanmugam VK, Steen VD. Curr Opin Rheumatol 2012;24(6):669-76
- [6] Borchers AT, Naguwa SM, Keen CL & Gershwin ME. Clin Rev Allergy Immunol 2003;25:89-104.
- [7] Nocturne G and Mariette X. Nature Rev Rheumatol 2013;9:544-556.
- [8] Perrier S, Coussediere C, Dubost JJ, Albuissou E, Sauvezie B. Clin Immunol Immunopathol 1998;**87** (3): 309–13.
- [9] Carine Salliot, Luc Mouthon, Marc Ardizzone, Jean Sibilia, Loïc Guillevin, Jacques-Eric Gottenberg and Xavier Mariette. Rheumatology 2007;46 (2): 321-326.
- [10] Fox RI. Lancet 2005;366: 321-331.
- [11] Avouac J, Sordet C, Depinay C, et al. Arthritis Rheum 2006; 54: 2243-9
- [12] scleroderma Overlap syndrome Alexandra Balbir-Gurman MD and Yolanda Braun-Moscovici MD
- [13] Cipoletti JF, Buckingham RB, Barnes EL et al. Ann Intern Med 1977; 87:535–41.
- [14] Osial TA, Jr, Whiteside TL, Buckingham RB et al. Arthritis Rheum 1983; 26:500–8.
- [15] Drosos AA, Andonopoulos AP, Costopoulos JS, Stavropoulos ED, Papadimitriou CS, Moutsopoulos HM. J Rheumatol 1988; 15:965–8.
- [16] Vitali C, Bombardieri S, Jonsson R et al. Ann Rheum Dis 2002.